

The CNS Paraneoplastic Syndrome: A Review of the Pathogenesis, Types, Manifestations and Diagnosis

Adedeji Okikiade ^{a*}, Edward Taylor ^a, Norhan Abdulrahman ^a,
Oyeni Imoleayo ^a, Miriam Tikanide ^a, Aromedonghene Osharode ^a
and Damisola Ogunesan ^b

^a College of Medicine, All Saints University, Saint Vincent and the Grenadines.

^b Lagos University Teaching Hospital, Idi-Araba, Lagos, Nigeria.

Authors' contributions

This work was carried out in collaboration among all authors. All authors read and approved the final manuscript.

Article Information

Open Peer Review History:

This journal follows the Advanced Open Peer Review policy. Identity of the Reviewers, Editor(s) and additional Reviewers, peer review comments, different versions of the manuscript, comments of the editors, etc are available here: <https://www.sdiarticle5.com/review-history/92089>

Review Article

Received 20 July 2022
Accepted 29 September 2022
Published 11 October 2022

ABSTRACT

Paraneoplastic Neurological Syndromes (PNS) are a rare spectrum of non-metastatic manifestations likely secondary to T-cell or auto-antibodies induced neuronal dysfunction or cell death and are mostly associated with soft tissue cancers. PNS arises from either the cell membrane binding site of antineuronal antibodies causing protein dysfunction or from the antibodies that bind to the intracellular antigens leading to necrosis of the cell. The neurological paraneoplastic phenotypes are numerous. Encephalomyelitis, acute cerebellar degeneration, Limbic Meningoencephalitis (LE), and dorsal sensory neuropathy are a few of them worth discussing. Specific antibodies are sometimes associated with specific underpinning tumor types. Screening for malignancy is important for all patients suspected of paraneoplastic neurological manifestations. Urgent biotherapy initiation is important in treating patients with the paraneoplastic neurological syndrome. It is more effective in cell surface antibodies than intracellular antibodies, as it removes the inexplicit tumor. This review article aims to elucidate the possible etiopathogenic patterns of different types of PNS.

*Corresponding author: E-mail: okikis@yahoo.com;

Keywords: Cancer; paraneoplastic syndrome; paraneoplastic neurological syndrome; antibodies; limbic system; Opsoclonus-myoclonus; encephalitis.

ACRONYMS

PSN : Paraneoplastic Sensory Neuronopathy

NMDA : N-Methyl-D-Aspartate

PNH : Peripheral Nerve Hyperexcitability

GAD : Lutamic Acid Decarboxylase

1. INTRODUCTION

Paraneoplastic neurological syndrome (PNS) is defined as distant systemic effects of a tumor that are absolutely unrelated to metastasis. The term was first described in 1949 by Guichard and Vignon [1].

Paraneoplastic neurological syndrome (PNS) can affect any part of the nervous system and then present with stereotyped clinical manifestations. They mostly occur in association with cancers and have immune-mediated pathogenesis, which is supported by the frequent presence of specific neuronal antibodies without a primary tumor in the nervous system [2,3]. It is important to know that symptoms of unclear cause in the presence of cancer can be called paraneoplastic syndrome. The PNS are seen in the brain, spinal cord, peripheral nerves, and the visual system (Retina).

Paraneoplastic neurological syndrome could be grouped as classical and non-classical. Examples of classic PNS are; encephalomyelitis, cerebellar degeneration, opsoclonus-myoclonus, dermatomyositis, Lambert Eaton(LEMS), and Myasthenia Syndrome(MG), Dermatomyositis, Sensory neuropathy, and intestinal pseudo-obstruction cancer. examples of non-classical PNS are brain stem encephalitis, stiff-person syndrome, necrotizing myelopathy, Guillan-Barre syndrome, optic neuritis, polymyositis, vasculitis, sensorimotor and autonomic neuropathies, melanoma-associated retinopathy, optic neuropathy and acute necrotizing myopathy [2-4]. They are classified as non-classical because they resolves spontaneously or symptoms are alleviated after the treatment of primary cancer. These myriads of PNS can be associated with cancers of the lungs, thymus, plasma cells, breasts, ovaries, skin, and gonads.

2. EPIDEMIOLOGY

The review suggests PNS occurs in roughly 20% of middle-aged cancer patients. PNS are not

noticed in many cases, meaning that the patient's complaint may be due to problems other than the immunological system. It affects both males and females equally. Although commoner in older patients, it could also occur in children and teenagers. As the incidence is unknown due to its rarity, it can occur with any malignancy [2]. The reported prevalence of paraneoplastic syndromes varies between 10-15% and 2-20% of malignancies, but these numbers may be understated [4,5]. Less than 1% of cancer patients are thought to develop neurological paraneoplastic disorders. Similar to this, it is unknown how common paraneoplastic syndromes are in terms of mortality and consequences. There is no information on a racial preference for paraneoplastic disorders. No known sex preferences exist. Cancers and paraneoplastic disorders can afflict people of all ages [5,6].

3. PATHOPHYSIOLOGY

The etiology of PNS is not established. Complications such as infection or side effects of treatment are not caused by PNS. Rather they occur side by side with cancer due to the immune system being activated via antibody production or T-cell-mediated pathogenesis. When activated, these agents attack the nervous system's normal cells leading to neurological disorders [6-8]. The pathophysiology of paraneoplastic diseases is intricate and fascinating. Attack of the spinal cord, muscles, or peripheral nerves and part of the brain by the cancer-fighting agents of the immune system leads to paraneoplastic syndromes of the nervous system. Problems with sensory perception, muscle movement, thinking skills, and sleep can occur depending on the site where the nervous system is affected. Therapy directed toward cancer and the immune system sometimes reverses the injury. However, irreversible damage can occur due to severe damage to the nervous system.

In either situation, treating underlying cancer and other interventions may prevent further damage, improve symptoms and give patients a better quality of life [7-9]. The body may respond to the situation by creating antibodies in response to the development of a tumor that binds to and kill tumor cells. Unfortunately, these antibodies occasionally attack healthy tissues and cause cross-reactivity, which can lead to paraneoplastic

manifestations. For instance, T cells or antibodies meant to combat the tumor can harm healthy nerve cells. In 1965, the discovery of a paraneoplastic anti-neural antibody was initially documented. In some instances, paraneoplastic syndromes are caused by the tumor's synthesis and release of chemicals with physiological activity [Fig. 1]. Hormones, hormone precursors, enzymes, or cytokines can all be produced by tumors. Multiple malignancies produce proteins that are biologically produced by fetal and embryonic cells in utero but not by normal cells and can also be implicated [10].

3.1 Antibodies and Associated Neoplasia

There are several antibodies with known associated paraneoplastic syndromes and cancers [3,10]. Cancers may be linked to a nervous system paraneoplastic syndrome. However, those who have tumors of the respiratory (small cell lung cancer), ovarian (ovary), breast, testicular (testis), or lymphatic system are more likely to develop the diseases [11].

The antibody association may be characterized fully or partially in different cancer types, and in some cases, they are not present. It was earlier proposed that T-cell-mediated paraneoplastic syndrome may not have established antibodies [8,11,12]. Table 1 summarizes the antibodies characteristics with the associated malignant tumor and paraneoplastic syndrome. There are well characterized antibodies, and these are those directed against known antigens or that have been reported by numerous investigators (see Table 1a). Likewise, some cancers have partially characterized antibodies and the list seen on Table 1b, while some are equivocal in their entirety (see Table 1c) [3,10-12].

In another set of recent studies, other forms of antibodies are discovered in association with commoner neurological paraneoplastic syndromes. The number of cases was low. They are mostly identified antibodies in patients with cerebellar degeneration, opsoclonus-myoclonus, and limbic encephalitis. Table 2 shown below summarized the recent antibodies discovered and associated PNS, cancers, number of cases known and pertinent observation [3,10-12].

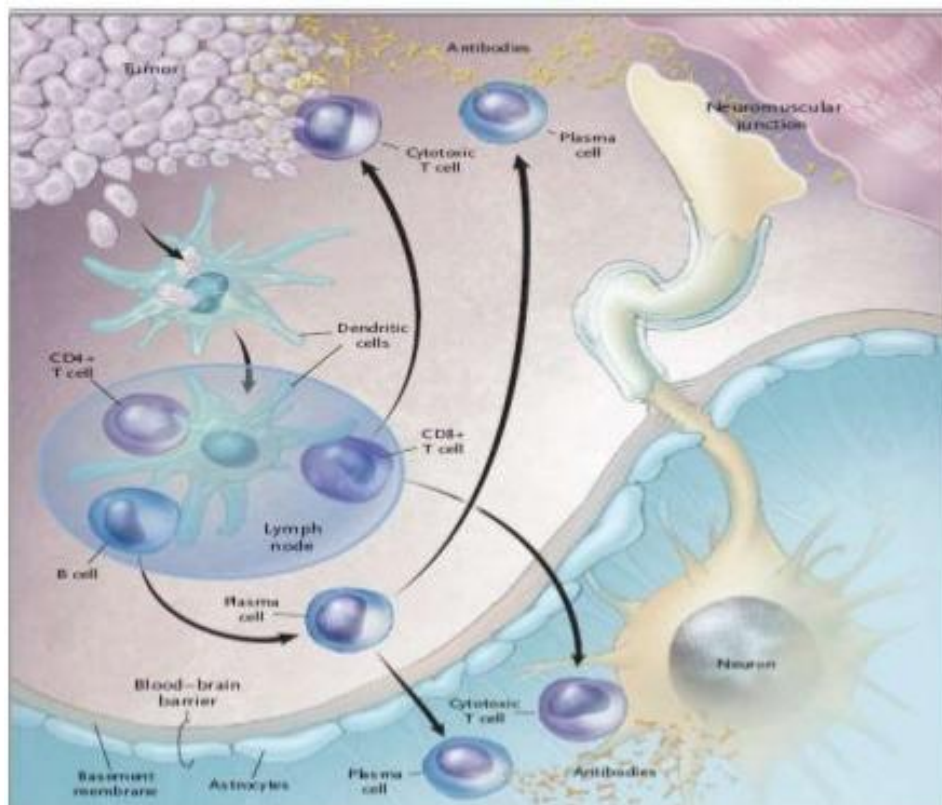


Fig. 1. Schematic of the pathogenesis of CNS paraneoplastic syndrome

Source: <https://image.slidesharecdn.com/paraneoplastic syndromes-170323175410/95/paraneoplastic-syndromes-cns-manifestations-8-638.jpg?cb=1490291908>

Table 1a. Well characterized paraneoplastic antibodies

Antibodies	Syndrome	Associated cancer
Anti-Hu (ANNA-1)	Paraneoplastic Encephalitis (PEM) including cortical, limbic, brainstem encephalitis, Paraneoplastic Cerebellar Degeneration (PCD), myelitis, neural dysfunction.	Small Cell Lung Cancer (SCLC) Genitourinary cancers
Anti-Yo (PCA-1)	PCD	Gynecological, breast
Anti-Ri (ANNA-2)	PCD, brainstem encephalitis, opsoclonus-myoclonus	Breast, gynecological, SCLC
Anti-CV2/CRMP5	PEM, PCD, chorea, uveitis, optic neuritis, peripheral neuropathy	SCLC, thymoma, other
Anti-Ma proteins	Limbic, hypothalamic, brainstem encephalitis (infrequently PCD)	Germ-cell tumors of testis, non-SCLC, other solid tumors
Anti-amphiphysin	Stiff-person syndrome, PEM, limbic encephalitis, myelopathy	SCLC, breast

Table 1b. Partly characterized paraneoplastic antibodies

Antibodies	Syndrome	Associated cancer
Anti-Tr	PCD	Hodgkin's lymphoma
Anti-Zic 4	PCD	SCLC
mGluR1	PCD	Hodgkin's lymphoma
ANNA3	Various PND of the CNS	SCLC
PCA2	Various PND of the CNS	SCLC

Source: Dalmau et.al [4]. <https://www.ncbi.nlm.nih.gov/pmc/articles/PMC2367117/>

Table 1c. Antibodies that occur with and without cancer association

Antibodies	Syndrome	Associated Cancer
Anti-NR1/NR2 of NMDA receptor	Characteristic encephalitis§	Teratoma (usually in the ovary)
Anti-VGKC	Limbic encephalitis, PNH (neuromyotonia),	Thymoma, SCLC, other
Anti-VGCC	LEMS, PCD	SCLC
Anti-AChR	MG(Reaction against cell antigens)	Thymoma
Anti-nAChR	Subacute pandysautonomia	SCLC, others
Anti-GAD	Stiff-person syndrome, cerebellar ataxia, limbic encephalitis, other	Thymoma, other

Source: Dalmau et.al [4]. <https://www.ncbi.nlm.nih.gov/pmc/articles/PMC2367117/>

3.2 Newly Discovered Antibodies and Associated Neoplasia

In another set of recent studies, other forms of antibodies are discovered in association with commoner neurological paraneoplastic syndromes. The number of cases was low.

These antibodies have mostly been identified in patients with cerebellar degeneration, opsoclonus-myoclonus, and limbic encephalitis. Table 2 summarizes the recent antibodies discovered and associated with PNS, cancers, the number of known cases, and pertinent observations [3,4,12-14].

Table 2. Newly discovered antibodies and associated neoplasia

Antibodies	Syndrome	Tumor	Number of cases	Comments
CARP VIII	PCD	Melanoma	1	Highly in the cerebellum
Zic1, Zic 4	PCD	SCLC	18	Mutations associated with cerebellar malformation (Dandy-Walker)
PKC γ	PCD	Non-SCLC	1	Missense mutations of PKC γ result in autosomal dominant cerebellar ataxia (SCA14)
Proteasome	PCD	Ovary	12	Anti-Yo antibodies may be positive
Neuroleukin	Opsoclonus	No tumor	2	Post-streptococcal
Gliadin, IgA subtype	Opsoclonus	No tumor	1	Celiac disease; patient also had endomysial and CV2 antibodies
Adenomatous polyposis coli	Opsoclonus	2 SCLC, 2 idiopathic	4	Protein highly expressed in brainstem, cerebellum and hippocampus; 2 of 4 patients had opsoclonus, the other 2 had nystagmus, diplopia, ataxia
Zic2	Opsoclonus	SCLC	1	Same as other Zic
Anti-BR serine/threonine kinase 2	LE	SCLC	1	..
Antibodies to CRMP3-4	LE	Thymoma	1	GAD antibodies positive
Adenylate kinase 5	LE	No tumor	2	Refractory to treatments
GluR ϵ 2	LE	Ovarian teratoma	1	Described in many other disorders. Different from anti-NR1/NR2 heteromers of NMDA receptor

Source: Dalmau et.al [4]. <https://www.ncbi.nlm.nih.gov/pmc/articles/PMC2367117/>

4. CLINICAL MANIFESTATIONS

Paraneoplastic neurologic syndromes primarily depends on the location in the nervous system (Limbic system, brain stem, cerebellum, nerves, cerebrum ,neuromuscular junctions),and may

present as encephalitis, ataxia, neuropathy with progressive numbness and weakness of feet and hands, myoclonus, opsoclonus, psychiatric disturbances, and Lambert-Eaton myasthenic syndrome that causes extreme weakness of several muscle groups, including those that

control breathing. It is the presence of specific paraneoplastic antibodies that often leads to the manifestations and diagnosis of paraneoplastic neurologic syndrome [12,13].

Common presentations may include difficulty walking, maintaining balance and loss of muscle coordination, loss of muscle tone or weakness and unusual involuntary movements, loss of fine motor skills, such as picking up objects, difficulty swallowing, slurred speech, stuttering (dysarthria.), memory loss, myelitis (myelopathy), neuropathies, cognitive impairment, seizures, hallucinations, virtual impairment (cranial nerve palsy, cataract, retinopathy) and sleep disturbances [3,12].

Encephalitis associated with Anti-NMDA receptor may present with prominent psychiatric symptoms, memory impairment, vertigo, hypoventilation, nystagmus, and altered consciousness with frequent hypoventilation, dysfunctional autonomic system, and dyskinesia [3]. The other manifestations can develop quickly, often over days to weeks, and may often begin before a cancer is diagnosed.

There are numerous diseases (differentials) that may present in a very similar way like PNS. Table 3 shows different types of PNS and most likely diseases that share similar manifestations.

5. DIAGNOSTIC FINDINGS

There is evolution in the diagnostic pattern and criteria of PNS in the past 16 years. Advancement in medical science and technology has so far improved and various hypothesis are proposed in the diagnosis. Below explains the possible laboratory findings in Paraneoplastic neurological syndrome (PNS), and evolution of the diagnostic parameters.

5.1 Imaging, CSF (Cerebrospinal Fluid) and Serum Antibodies Assessment

Paraneoplastic neurological syndrome (PNS) antibodies in the serum and CSF for antibodies are valuable, followed by the use of MRI to support the findings and exclude differentials.

Table 3. Differentials of PNS

PNS	Differential diagnosis	Other possibilities in patients with cancer
Paraneoplastic cerebellar degeneration	Alcohol toxicity Vitamin deficiency (thiamine, vitamin E) Toxins (anticonvulsants, other) Infectious or postinfectious cerebellitis Miller-Fisher syndrome. GAD-associated cerebellar ataxia. Gliadin-associated cerebellar ataxia. Creutzfeldt-Jacob disease.	Cerebellar metastasis. Chemotherapy toxicity (fluorouracil, cytarabine).
Opsoclonus-myoclonus	Infectious (Bacterial, fungal and viral), postinfectious encephalitis. Hyperosmolar coma. Side-effects of drugs (amitriptyline, lithium, phenytoin and diazepam) Intracranial haemorrhage Systemic disease (HIV/AIDS, sarcoidosis, Viral hepatitis, Celiac sprue)	Intracranial tumors or metastasis Hydrocephalus
Limbic encephalitis and variants	Herpes simplex virus encephalitis(HSV-1) Sjögren's syndrome Hashimoto's encephalopathy Systemic lupus erythematosus(SLE) Toxic-metabolic encephalopathy Korsakoff's syndrome (thiamine deficiency) Syphilis infection Primary angiitis of the CNS	Brain metastasis Herpesvirus 6 limbic encephalitis (in particular after bone marrow transplantation) Low grade glioma Gliomatosis cerebri

Magnetic resonant Imaging (MRI) and early findings in Paraneoplastic Cerebellitis will show pleocytosis, increased protein concentration, and high titers of anti-Tr, anti-Hu, anti-Ri, anti-Yo,

anti-Ma and anti-CRMP5 antibodies .These are highly suggestive [3]. Fig 2a and 2b show the algorithmic approaches once adopted in the management of PNS [3,14,15].

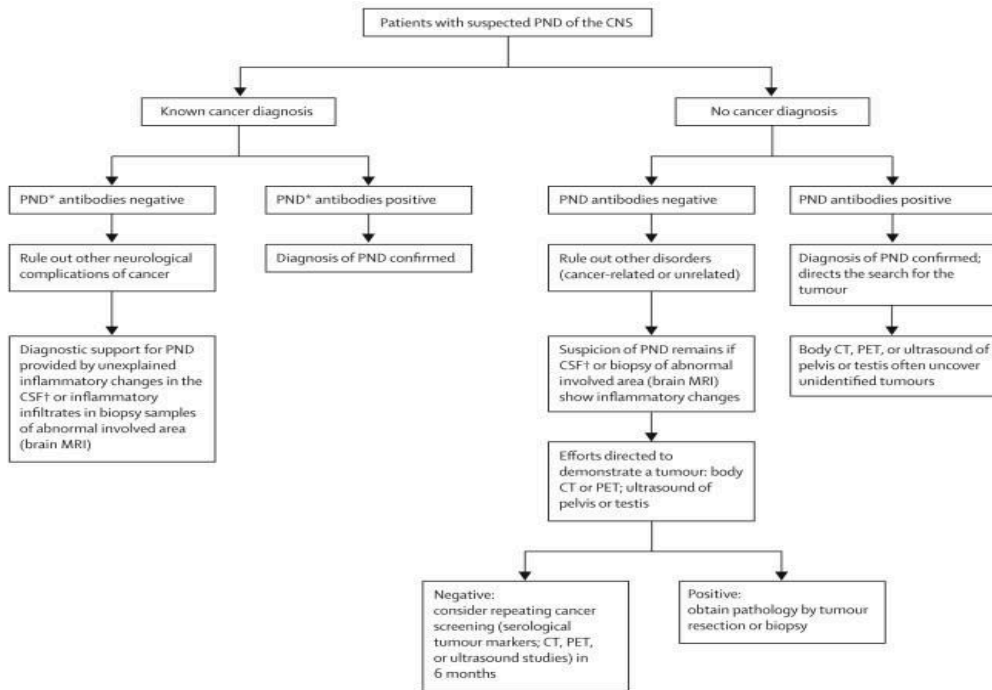


Fig. 2a. Diagnostic approach to PND of the CNS – Lancet Neurol, 2008 (outdated)
 Source: <https://pubmed.ncbi.nlm.nih.gov/18339348/>

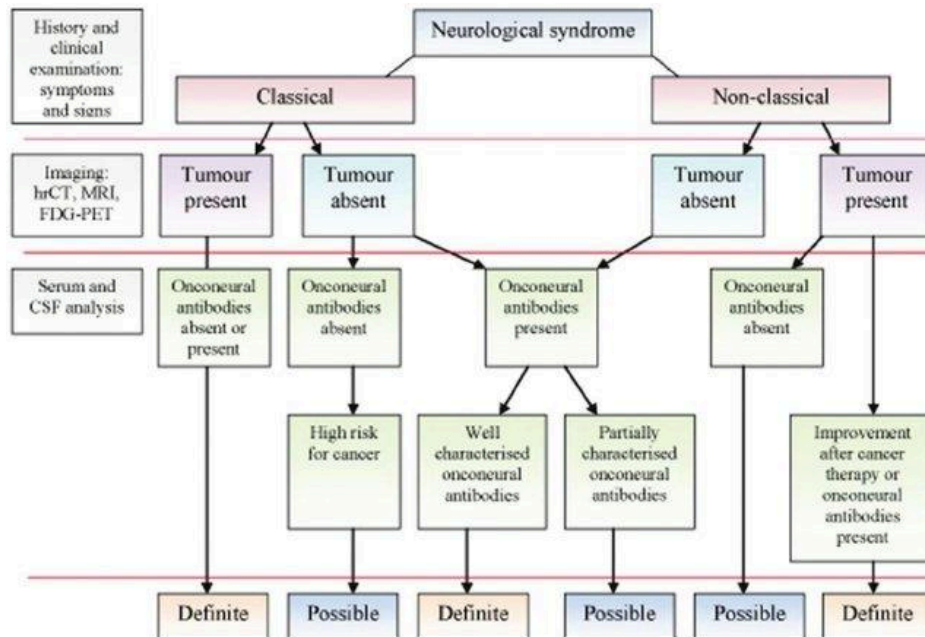


Fig. 2b. Diagnostic algorithm for the definite or possible diagnosis of paraneoplastic syndrome (modified)

Source: Paraneoplastic neurological syndromes in older people (researchgate.net, 2012)

The paraneoplastic antibody type helps to direct tumor search to a specific organ (for example, most Hu antibody positive patients have lung cancer). MRI is normal in most patients initially.

Some patients have diffuse cerebellar hemispheric enlargement in the sulci of the cerebellar vermis, as seen in the contrast enhancement MRI in Figs. 4,5 [3,14,16].

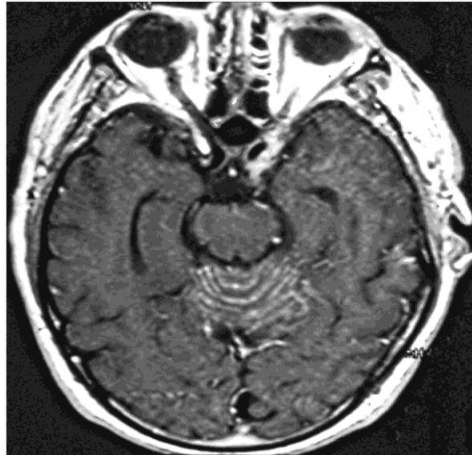

Fig. 3. Early MRI showing inflammation of the cerebellum in Non-Hodgkin lymphoma (PNS)

Source: <https://www.ncbi.nlm.nih.gov/pmc/articles/instance/2367117/bin/nihms-45999-f0002.jpg>

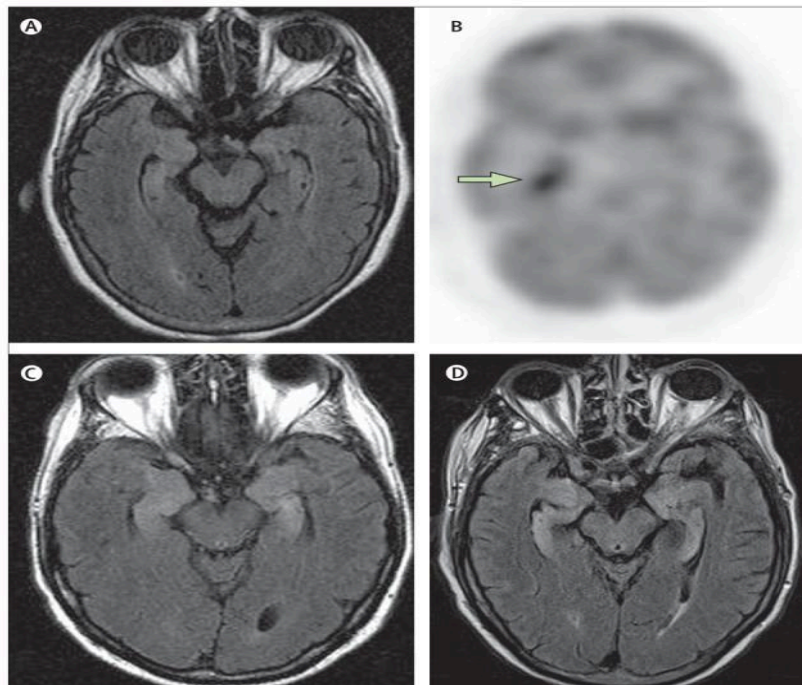


Fig. 4. Neuroimaging of patients with encephalitis. A and B: patient with anti-Hu-associated sensory neuropathy. MRI of the brain (A) was normal. (B). A body fluorodeoxyglucose-PET scan that included the brain revealed an area of hypermetabolism in the right hippocampus C: typical increased FLAIR signal involving the hippocampi of a patient with paraneoplastic limbic encephalitis. D: medial temporal lobe FLAIR abnormalities and atrophy in a patient with a liver transplant who developed human herpes virus 6 (HHV6) encephalitis (mimicker of PNS-limbic encephalitis)

Source: <https://www.ncbi.nlm.nih.gov/pmc/articles/PMC2367117/>

5.2 Electroencephalogram (EEG)

This may be valuable in excluding seizure disorders. In PNS, periodic lateralized epileptiform discharges (PLEDs) and frontal intermittent rhythmic delta activity (FIRDA) may be seen [3]

5.3 Histopathology

Extensive Purkinje cell loss is an identifying mark of paraneoplastic cerebellar degeneration. This is illustrated below in Fig. 2. In slide A, no

remaining Purkinje cells are visible. CD3 T cells form clusters, as seen in arrows at the level of the Purkinje cell layer. Slide B is under higher magnification, and the arrow points to a neuronopathic nodule of T lymphocytes that likely destroys a Purkinje cell. This is associated with encephalomyelitis and anti-Hu antibodies [16].

5.4 Whole Body PET and CT Scan

This is valuable in detecting occult cancer in patients with PNS. The sensitivity is very high, >95%. [17]

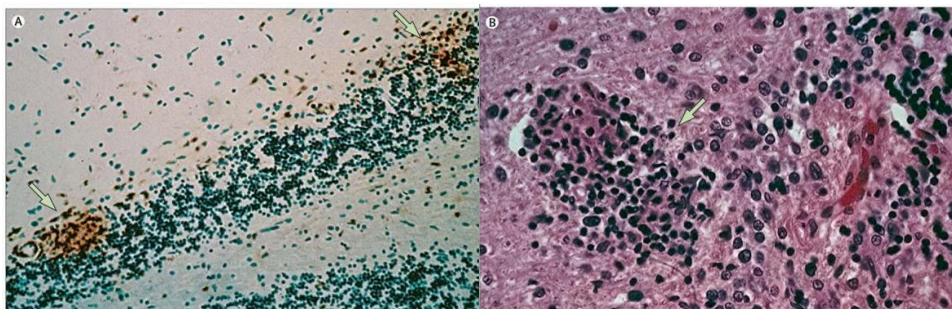


Fig. 5. Histograph showing inflammatory infiltrates in subacute cerebellar degeneration

Source: <https://www.ncbi.nlm.nih.gov/pmc/articles/PMC2367117/>

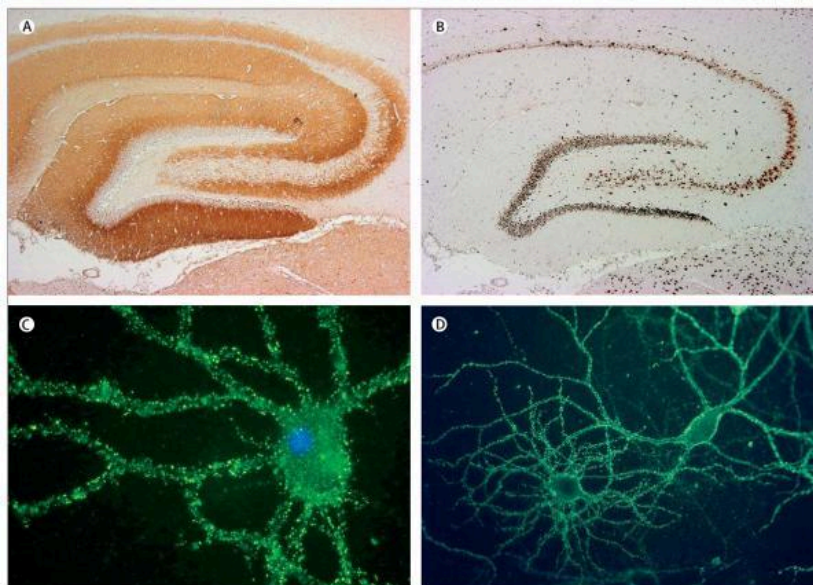


Fig. 6. Antibodies associated with paraneoplastic encephalitis. A and B: antibody reactivity in a rat brain with antibodies to NR1/NR2 heteromers of the NMDA receptor (A) and anti-Hu antibodies (B). Anti-NMDA receptor antibodies produce intense immunolabelling of the neuropil of the hippocampus whereas anti-Hu antibody staining is limited to neuronal cell bodies. C: cultures of non-permeabilised live neurons immunolabelled by antibodies contained in the CSF of a patient with anti-NMDA-receptor encephalitis. D: similar cultures immunolabelled with the CSF of a patient with limbic encephalitis and cancer of the thymus. A and B: immunoperoxidase technique. C and D: immunofluorescence

Source: <https://www.ncbi.nlm.nih.gov/pmc/articles/PMC2367117/>

5.5 Other Supportive Investigations

The aim of these investigations is to exclude possible differentials, side effects of medications and complications of the cancer and PNS. Paraneoplastic Syndrome is rare, and differential diagnoses will be observed more frequently. It is important to diagnose correctly and treat appropriately. The patient's demographic features and the clinical presentation should be indicated in the differential diagnosis [17,18].

Baseline investigations to exclude diabetes mellitus (blood sugar), thyroid disorders (TSH), renal and liver function tests (RFT, LFT) should be done.

Nonparaneoplastic diseases, infections, tumors, neurodegenerative disorders, and other metabolic disturbances should also be considered and ruled out before diagnosis and treatment. The symptoms of paraneoplastic neurological disorders (PNDs) may present like Creutzfeldt-Jacob Disease (CJD). The 14-3-3 protein in the CSF is helpful for the diagnosis of Creutzfeldt-Jacob Disease (CJD) [19]. However, this protein was also found in 12.5% of patients with paraneoplastic neurological disorders (PNDs) [20]. Urine and blood toxicology to rule of drug and medication toxicity. Screen for infectious agents HIV (ELISA, WESTERN BLOT), PCR for Varicella virus, spirochete, EBV, HBsAg test, VDRL for syphilis, Tuberculosis (Manteoux test) [15,21]. Other differentials include cerebellitis and glutamic-acid-decarboxylase-associated cerebellar degeneration. This latter syndrome has milder ataxia which mainly affects gait and a slower progression [15].

In view of the complexity, 2004 PNS criteria was partially outdated and subsequently updated in 2021. The updated criteria was employed as a results of the heterogeneity of the immunological, oncological and clinical manifestations. The panel adopted a scoring system (PNS –Care Score) that uses the antibody type, cancer presence, clinical phenotype and follow up time to categorize the patients. High risk phenotypes (>70% associated with cancer) and intermediate risk phenotypes (30-70% associated cancer) antibodies are the main categorization used to enhance care and foster research initiatives in PNS [17].

6. MANAGERMENTS

The treatment of paraneoplastic syndromes involves treating the cancer or immune system

suppression in order to reduce the signs and symptoms, which depend on the type of the specific paraneoplastic syndrome [21,22]. The treatment is generally complex with poor outcomes. Mostly palliative and supportive treatments are also available.

Medications:

- **Corticosteroids**, such as prednisone inhibit inflammation [8,21-23].
- **Intravenous immunoglobins** ; mop up the antibodies in the blood [1,8,23]
- **Immunosuppressants**; reduces white blood cell production causing the disease [8,23].
- **Anti-seizure medications**; these medications can control Paraneoplastic syndrome-associated seizures causing electrical instability [8,23].
- **Some medications are useful in enhancing nerve-to-muscle transmission**, thereby improving symptoms of paraneoplastic syndromes affecting muscle functions [8,23].

There are measures that are helpful in paraneoplastic syndrome induced disability:

Physiotherapy: Muscle and nerve damages with loss of functions can be regained with the help of some specific exercise. A licensed physiotherapist maybe involved to achieve optimal outcome [8].

Speech therapy: Helps with problems in speaking or swallowing. A speech therapist helps in relearning the necessary muscle control.

Plasmapheresis: This is a process of removal of antibodies from the blood .It may be useful in PNS as documented in a study of 7 patients managed by plasmapheresis and immunosuppressant with equivocal outcome [8,23].

7. PROGNOSIS

This is generally poor for most patients, because most of them die from cardiopulmonary arrest from brain stem or autonomic dysfunction, pneumonia, unresponsive epilepsy and organ failure. The outcome may be better in male, young patients on treatment with early detection, absence of metastasis and presence of anti-MA-2 antibodies [5].

8. CONCLUSION

The incidence and prevalence of cancers are increasing by day, and patients are living longer with the advancement in medicine, invariably paraneoplastic syndromes in patients will increase. These conditions affect the clinical course, presentation, management and treatment of cancer [23]. As a result of the current diagnostics, many paraneoplastic syndromes are recently well defined and have a clear pathogenesis and effective management options [8,22,23].

The ability to diagnose and treat paraneoplastic syndromes may have a significant effect on clinical outcomes which are differing from earlier cancer diagnosis resulting in improved life quality and raised or increased delivery of tumor-directed therapy [18,22]. Ongoing research works into these disorders may increase insight into the mechanisms of tumor development, maintenance, and proliferation.

This is a rare and often undiagnosed or misdiagnosed disease complex, which requires high index of suspicion and research funding. This will be essential in improving the existing knowledge and chart a course for better diagnosis, treatment, and possible cure of PNS. The prognosis is generally not good because the patient may die of cancer or complications from therapy, and may be associated with cardiopulmonary failure [8,15,21,23].

CONSENT

It is not applicable.

ETHICAL APPROVAL

It is not applicable.

COMPETING INTERESTS

Authors have declared that no competing interests exist.

REFERENCES

1. Paraneoplastic Syndromes: Symptoms, Causes, Treatments & Tests. Cleveland Clinic, my.clevelandclinic.org/health/diseases/17938-paraneoplastic-syndromes.
2. Guichard MMA, Cabanne F, Tommasi M, Fayolle J. Polyneuropathies in cancer patients and paraneoplastic polyneuropathies. *Lyon Medecine*. 1956;41:309–29.
3. Lawn ND, Westmoreland BF, Kiely MJ, Lennon VA, Vernino S. Clinical, magnetic resonance imaging, and electroencephalographic findings in paraneoplastic limbic encephalitis. *Mayo Clin Proc*. 2003;78:1363–68.
4. Dalmau J, Rosenfeld MR. Paraneoplastic syndromes of the CNS. *Lancet Neurol*. 2008 Apr; 7(4):327-40. DOI: 10.1016/S1474-4422(08)70060-7. PMID: 18339348; PMCID: PMC2367117.
5. Thapa B, Mahendrakar N, Ramphul K. Paraneoplastic Syndromes. [Updated 2022 Jul 23]. In: StatPearls [Internet]. Treasure Island (FL): StatPearls Publishing; 2022. Available: <https://www.ncbi.nlm.nih.gov/books/NBK507890/>.
6. Tanaka K. [Pathogenesis of paraneoplastic neurological syndromes]. *Brain Nerve*. 2010;62(4):309-18. Japanese. PMID: 20420170.
7. Erlich R, Morrison C, Kim B, Gilbert MR, Alrajab S. ANNA-2: An antibody associated with paraneoplastic opsoclonus in a patient with large-cell carcinoma of the lung with neuroendocrine features—correlation of clinical improvement with tumour response. *Cancer Invest*. 2004;22:257–61
8. Graus F, Vega F, Delattre JY, et al. Plasmapheresis and antineoplastic treatment in CNS paraneoplastic syndromes with antineuronal autoantibodies. *Neurology*. 1992;42:536–40.
9. Honnorat J, Viaccoz A. New concepts in paraneoplastic neurological syndromes. *Rev Neurol (Paris)*. 2011;167(10):729-36. DOI: 10.1016/j.neurol.2011.08.001. Epub 2011 Sep 3. PMID: 21890156.
10. Khan F, Kleppel H, Meara A. Paraneoplastic Musculoskeletal Syndromes. *Rheum Dis Clin North Am*. 2020;46(3):577-586. DOI: 10.1016/j.rdc.2020.04.002. Epub 2020 Jun 7. PMID: 32631605.
11. “Paraneoplastic Neurologic Syndromes - NORD (National Organization for Rare Disorders).” NORD (National Organization for Rare Disorders), NORD; 2015. rarediseases.org/rare-

- diseases/paraneoplastic-neurologic-syndromes/
12. Zalewski NL, Pittock S.J. (2019). Paraneoplastic Neurologic Disease. In: Cho, T., Bhattacharyya, S., Helfgott, S. (eds) *Neurorheumatology*. Springer, Cham. Available: https://doi.org/10.1007/978-3-030-16928-2_15
 13. "Paraneoplastic Syndromes of the Nervous System - Symptoms and Causes." Mayo Clinic; n2017.
 14. Gultekin SH, Rosenfeld MR, Voltz R, Eichen J, Posner JB, Dalmau J. Paraneoplastic limbic encephalitis: neurological symptoms, immunological findings and tumor association in 50 patients. *Brain*. 2000;123:1481–94.
 15. Viau M, Renaud MC, Grégoire J, Sebastianelli A, Plante M. Paraneoplastic syndromes associated with gynecological cancers: A systematic review. *Gynecol Oncol*. 2017;146(3):661-671. DOI: 10.1016/j.ygyno.2017.06.025. Epub 2017 Jun 24. PMID: 28655412
 16. Dalmau, Josep. "Paraneoplastic Neurologic Syndromes - NORD (National Organization for Rare Disorders)." NORD (National Organization for Rare Disorders), NORD; 2016. Available: <https://rarediseases.org/rare-diseases/paraneoplastic-neurologic-syndromes/>
 17. Graus, Francesc, et al. Updated Diagnostic Criteria for Paraneoplastic Neurologic Syndromes. *Neurology - Neuroimmunology Neuroinflammation*, 2021;8. Available: <https://nn.neurology.org/content/8/4/e1014>, 10.1212/NXI.0000000000001014
 18. Zerr I, et al. "Detection of 14-3-3 Protein in the Cerebrospinal Fluid Supports the Diagnosis of Creutzfeldt-Jakob Disease." *Annals of Neurology*. 1998;43(1):32–40, Available: pubmed.ncbi.nlm.nih.gov/9450766/, 10.1002/ana.410430109. Accessed 27 July 2022.
 19. Saiz A, Graus F, Dalmau J, Pifarre A, Marin C, Tolosa E. Detection of 14-3-3 brain protein in the cerebrospinal fluid of patients with paraneoplastic neurological disorders. *Ann Neurol*. 1999;46:774–77.
 20. Grisold W, Giometto B, Vitaliani R, Oberndorfer S. Current approaches to the treatment of paraneoplastic encephalitis. *Ther Adv Neurol Disord*. 2011;4(4):237-48.
 21. Pelosof LC, Gerber DE. Paraneoplastic syndromes: an approach to diagnosis and treatment. *Mayo Clin Proc*. 2010;85(9):838-54.
 22. Rosenfeld MR, Dalmau J. Diagnosis and management of paraneoplastic neurologic disorders. *Curr Treat Options Oncol*. 2013;14(4):528-38. DOI: 10.1007/s11864-013-0249-1. PMID: 23900965; PMCID: PMC3844017.
 23. Wiwanitkit V. Paraneoplastic and other autoimmune disorders of the central nervous system. *Neurohospitalist*. 2014;4(1):5. DOI: 10.1177/1941874413509633. PMID: 24381703; PMCID: PMC3869311.

© 2022 Okikiade et al.; This is an Open Access article distributed under the terms of the Creative Commons Attribution License (<http://creativecommons.org/licenses/by/4.0>), which permits unrestricted use, distribution, and reproduction in any medium, provided the original work is properly cited.

Peer-review history:
The peer review history for this paper can be accessed here:
<https://www.sdiarticle5.com/review-history/92089>